Case Report

A Completely Cast-Free, Digital Workflow for Fabricating an Implant-Supported Prosthesis with a New Coded Healing Abutment

Ju-Hyoung Lee*

Assistant Professor, Department of Dentistry, Catholic University of Daegu School of Medicine, Daegu 42472, Korea

*Corresponding author: Ju-Hyoung Lee, jus2u@cu.ac.kr

Abstract

The BellaTek Encode System introduced an innovative concept of a healing abutment-level impression. As the coded healing abutment is unscrewed only at the placement session, the mucosal barrier at an implant is preserved and the clinical process is simplified. The laboratory process is also streamlined, as the entire process of a definitive dental implant abutment is outsourced and a dental technician fabricates only a definitive crown on a modified cast by robotic drilling or a stereolithography additive cast. However, potential errors may occur in the fabrication process of the casts. In addition, this system is available to only a specific implant system. This article describes a fully integrated digital workflow to overcome the limitations with a newly developed coded healing abutment. With the merging of advanced digital technologies, an implant-supported prosthesis can be accurately fabricated in an hour with minimized abutment dis/reconnection and no physical cast.

Keywords: CAD/CAM, Digitally coded healing abutment, Intraoral digital scanner, Scan body

OPEN ACCESS

pISSN : 1229-5418
Implantology 2019; 23(1): 26-35
https://doi.org/10.32542/implantology.2019003

Received: October 18, 2018
Revised: February 22, 2019
Accepted: March 7, 2019

ORCID
Ju-Hyoung Lee
https://orcid.org/0000-0003-4201-6580

Copyright © 2019. The Korean Academy of Oral & Maxillofacial Implantology

This is an Open Access article distributed under the terms of the Creative Commons Attribution Non-Commercial License (http://creativecommons.org/licenses/by-nc/4.0/) which permits unrestricted non-commercial use, distribution, and reproduction in any medium, provided the original work is properly cited.

Ⅰ. Introduction

Due to the high survival rate of implant-supported prostheses (ISPs) and continuous advancements in implant prosthodontics over time, ISPs have proved to be a reliable treatment option[1,2]. Conventional impressions using open or closed tray impression transfer copings have been widely used for the accurate transfer of implant position to a definitive cast[3]. Recently, intraoral digital impressions using scan bodies have gained popularity due to the high level of impression accuracy, clinical efficiency, and increased patients' satisfaction[4-6]. However, repeated abutment dis/reconnection is still necessary during analog or digital impression procedures. Abrahamsson et al[7] described that repeated abutment change compromised the mucosal barrier and resulted in an apical positioning of the connective tissue. Peri-implant bone resorption was also observed to establish a proper biological width of the mucosal-implant barrier[7-9]. Therefore, minimizing the

number of abutment removal is desirable to reduce the bone resorption and to achieve better esthetic results and patients' convenience[7–9].

A digitally coded healing abutment (BellaTek Encode Healing Abutment, Zimmer Biomet, Palm Beach Gardens, FL, USA) can be an alternative[10–25]. It is remained until placement of an ISP after placing on the implant at the time of implant surgery or uncovering[10, 14–20]. After a conventional impression is made, a dental cast is sent to the machining center (BellaTek Production Center, Zimmer Biomet)[10–14, 18–20]. A laser scanner recognizes the embedded codes on the BellaTek Encode Healing Abutment that convey information relative to the implant hex position, the platform diameter, the connection type, and the height/width of the abutment[10–14, 19–21, 24, 25]. With computer–aided design and computer–aided manufacturing (CAD/CAM) technology, a definitive dental implant abutment is virtually designed and milled[10–14, 18–20]. With a robotic analog implant placement technique (Robocast Technology, Zimmer Biomet), a hole is made in the cast and an implant analog is manually placed into a hole with cyanoacrylate adhesive (Two–part cyanoacrylate adhesive, Zimmer Biomet)[14, 18–25]. The CAD/CAM abutment and the modified cast (Robocast, Zimmer Biomet) are shipped to a laboratory[14, 18–20, 25]. Therefore, a dental technician fabricates only a definitive crown[10–14, 18–20, 25].

Recently, the intraoral scanning technology has been applied to the BellaTek Encode System[15–17, 20]. After digitizing the BellaTek Encode Healing Abutment with an intraoral digital scanner (IOS), the scan data are electronically sent to the BellaTek Production Center and a patient–specific abutment is fabricated[15–17, 20]. Additionally, a stereolithography additive (SLA) cast is generated in 3M ESPE by using an abutment design file mailed from the BellaTek Production Center[15–17, 20]. The milled abutment and the printed cast are conveyed to a laboratory[15–17, 20]. Therefore, fabricating a Robocast or a SLA cast is required for subsequent fabrication of a definitive crown[14–20, 25]. Carpentieri and Lazzra[19] expected that the next technical advancement would be a completely cast–free, digital workflow for implant prosthodontics.

The purpose of the present article is to introduce a fully digital workflow with an advanced coded healing abutment. By using this streamlined process, an ISP can be rapidly fabricated without repeated abutment dis/reconnection, physical cast, and human error.

Ⅱ. Case Report

A 66–year–old male presented with pain in the maxillary right second molar. Based on the results of clinical and radiographic examinations, the diagnosis was a tooth fracture indicated for extraction. The

patient had no systemic diseases to undergo the surgical procedure. For the replacement of the tooth, advantages and disadvantages of a single dental implant were explained. The patient hoped to receive implant treatment. After an atraumatic extraction, a 4.5×10 mm bone level implant (Implantium, Dentium, Suwon, Korea) was placed in the first-stage dental implant surgery. A coded healing abutment (H-Scan Body, Dio Implant Inc, Busan, Korea) was hand tightened[19].

After 5 months, the complete placement of the H-Scan Body on the implant was reverified with an abutment driver dental implant (1.2 Hex Screw Driver, Dio Implant Inc) and a radiograph (Figs. 1 and 2)[19]. The H-Scan Body was circumferentially extended by 3 mm above the gingiva[19]. Plaque accumulation on the occlusal surface of the H-Scan Body was removed for the accurate superimposition in a CAD process. The maxillary right teeth and the H-Scan Body were scanned with an IOS (TRIOS Color Pod, 3Shape Inc, Copenhagen, Denmark) (Fig. 3)[26-29]. The antagonist teeth and maxillomandibular relationship was captured. The scan data, implant information, and H-Scan Body information were

Fig. 1. Coded healing abutment in place at the maxillary right second molar area.

Ju-Hyoung Lee: A Completely Cast-Free, Digital Workflow for Fabricating an Implant-Supported Prosthesis with a New Coded Healing Abutment. Implantology 2019

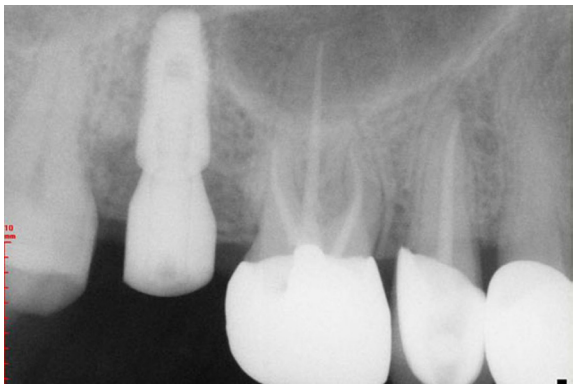

Fig. 2. Periapical radiograph of the proper placement of the coded healing abutment.

Ju-Hyoung Lee: A Completely Cast-Free, Digital Workflow for Fabricating an Implant-Supported Prosthesis with a New Coded Healing Abutment. Implantology 2019

transmitted to a laboratory.

By using a CAD program (Dental System, 3Shape Inc), the scan data were opened. The scanned image of the H-Scan Body was aligned with the stored image of the SB by using a 3-point matching technique (Figs. 4 and 5)[6]. A retrievable cemented ISP was planned for passivity and easy removal of excess cement[30-33]. A custom abutment and a crown with a screw-access opening were designed (Fig. 6)[30-33]. The finished design was transferred to 5-axis milling machines (Arum 5X-200, DoowonID Co, Daejeon, Korea). A titanium blank and a cobalt-chromium alloy block were milled simultaneously.

The H-Scan Body was removed and topical anesthetic (Beracaine Spray, Firson, Cheonan, Korea) was applied on the peri-implant soft tissue[34]. The custom abutment was secured to the implant up to three-fourths the recommended manufacturer instruction torque value[35, 36]. Proximal contacts and

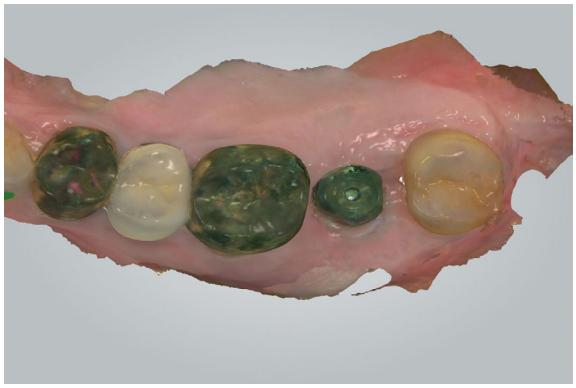

Fig. 3. Software view of the intraoral digital impression.

Ju-Hyoung Lee: A Completely Cast-Free, Digital Workflow for Fabricating an Implant-Supported Prosthesis with a New Coded Healing Abutment. Implantology 2019

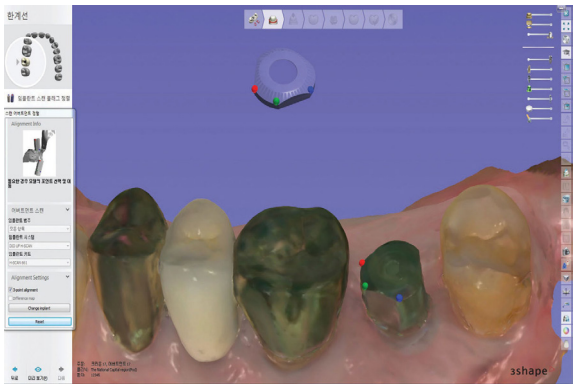

Fig. 4. Software view of the stored image of the coded healing abutment in the computer-aided design program. A 3-point matching technique is applied for the superimposition of the stored image and the scan image.

Ju-Hyoung Lee: A Completely Cast-Free, Digital Workflow for Fabricating an Implant-Supported Prosthesis with a New Coded Healing Abutment. Implantology 2019

occlusal contacts of the crown were evaluated and adjusted with an articulating film (AccuFilm II, Parkell Inc, Edgewood, NY, USA). The internal surface of the crown was abraded with 50 μm alumina oxide particles (Cobra, Renfert GmbH, Hilzingen, Germany) at 3 bar pressure for 10 seconds, at the distance of 10 mm from the nozzle of the sandblaster (Duostar, Bego, Bremen, Germany)[37]. After cleaning the crown, a primer (Monobond Plus, Ivoclar Vivadent Inc, Schaan, Liechtenstein) was applied to the internal surface. The crown was luted with resin cement (Multilink Automix, Ivoclar Vivadent Inc). After the polymerization, the ISP was retrieved extraorally and all excess cement was eliminated. The ISP was torqued on the implant according to the manufacture's protocol and the screw access channel was filled with silicone material[38, 39]. The screw-access opening was restored with composite resin (UniFil LoFlo Plus, GC Corp, Tokyo, Japan) (Fig. 7). At-home maintenance regime and recall appointments were provided[40, 41]. Stable peri-implant tissue was observed at 1 year follow-up (Fig. 8).

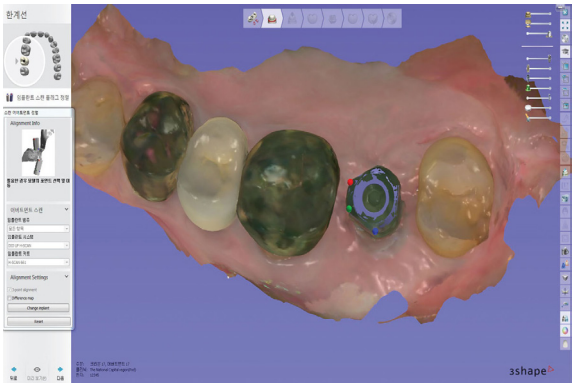

Fig. 5. Software view of the aligned image of the coded healing abutment with a 3-point matching technique.

Ju-Hyoung Lee: A Completely Cast-Free, Digital Workflow for Fabricating an Implant-Supported Prosthesis with a New Coded Healing Abutment. Implantology 2019

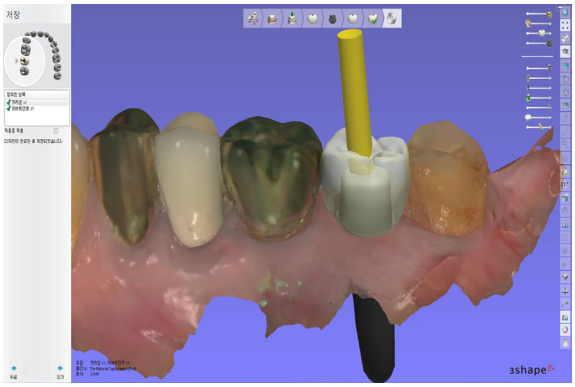

Fig. 6. Software view of the virtual design of the implant-supported prosthesis.

Ju-Hyoung Lee: A Completely Cast-Free, Digital Workflow for Fabricating an Implant-Supported Prosthesis with a New Coded Healing Abutment. Implantology 2019

Fig. 7. Implant-supported definitive prosthesis in place.

Ju-Hyoung Lee: A Completely Cast-Free, Digital Workflow for Fabricating an Implant-Supported Prosthesis with a New Coded Healing Abutment. Implantology 2019

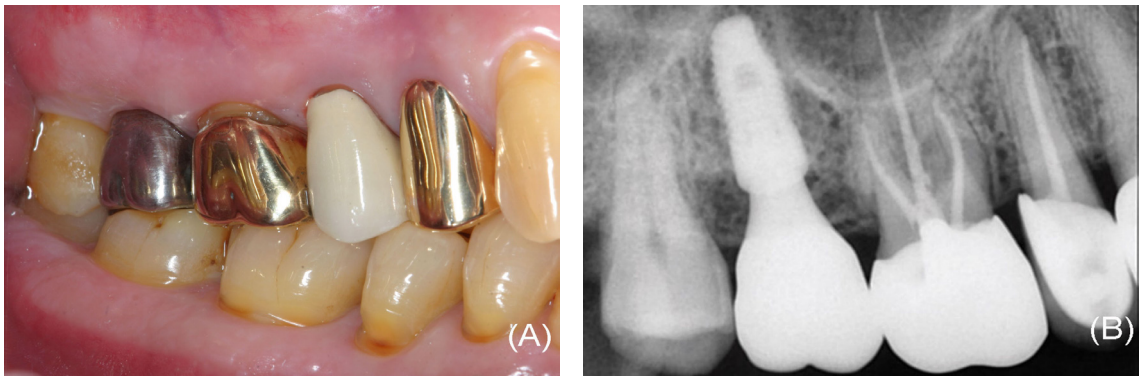

Fig. 8. Definitive result after 1 year. Note a stable peri-implant tissue.

Ju-Hyoung Lee: A Completely Cast-Free, Digital Workflow for Fabricating an Implant-Supported Prosthesis with a New Coded Healing Abutment. Implantology 2019

Ⅲ. Discussion

The BellaTek Encode system has been successfully applied in patients[10–20]. This innovative system minimizes peri–implant tissue irritation and provides a more efficient restorative process[10–20]. As the healing abutment–level impression is only necessary, this system is useful for a deeply placed implant[14–20]. It also saves a laboratory technician's time by eliminating labor–intensive procedures such as waxing and casting[10–20, 25]. However, this system has several limitations. First, use of this system is applicable only to a specific implant (Biomet 3i Dental Implants, Zimmer Biomet)[12, 14]. A second disadvantage is that total time to return an ISP from a laboratory is similar to a conventional protocol with a prefabricated abutment, due to the outsourcing production and the associated delivery time[25]. A third disadvantage is inaccurate positioning of an implant analog into a hole in a stone cast, due to the

robotic accuracy (100 um)[22], a slightly oversized hole (0.4 mm)[24], and polymerization shrinkage of the cyanoacrylate adhesive (17.8%)[23, 41]. Dimensional changes of impression materials[43] and dental stone[44] also increase the error. In addition, implant divergence negatively affects the Robocast accuracy[22, 24]. Even though an IOS and a SLA cast are used to reduce the cumulative error[15–17], marginal discrepancy may occur due to the lower accuracy and reproducibility of a SLA die[45, 46]. The outsourcing production of the CAD/CAM abutment in the BellaTek Production Center may cause the second and third drawbacks. Therefore, merging the BellaTek Encode and intraoral scanning technologies with the scan body technology is necessary to eliminate possible errors and to respond to the need for the outsourcing production.

Recently, the H-Scan Body is developed to overcome the aforementioned limitations. As this coded healing abutment is basically based on the BellaTek Encode Healing Abutment, it also reduces repeated abutment change, patients' discomfort, and chair time. The H-Scan Body can be applied various implants, if the CAD program has a library of installed implant. Another advantage is the accelerated fabrication of implant prostheses with the laboratory friendly CAD/CAM program.

However, this technique also has several limitations. One disadvantage is the initial purchasing costs for the IOS, the H-Scan Body, and its module. Another disadvantage is learning curve for intraoral scanning procedures, especially, in the posterior area, due to the limited space for the IOS head[16, 27, 28]. A third disadvantage is difficulty in establishing an ideal emergence profile due to the polygonal shape of the H-Scan Body[30], even if an algorithm formula is helpful to predict displacement of the soft tissue and the future position of the gingival margin after ISP placement[47]. Transient blanching and pain on insertion may occur[25]. Development of the wide H-Scan Body is necessary for easy seating of the ISP at the molar site. Even though the CAD/CAM abutments have exhibited the proper survival rate,48 postoperative care should be necessary to prevent unexpected complications[40, 41]. In addition, the influence of implant divergence on the three-dimensional accuracy of the impression technique using the H-Scan Body and compatibility of coded healing abutments should be investigated.

Ⅳ. Conclusion

This article describes the complete digital workflow for the ISP by using the H-Scan Body and the IOS. The fully integrated restorative process allows that the ISP can be placed with minimal adjustment. In addition, the peri-implant hard and soft tissues are preserved.

References

1. Pjetursson BE, Asgeirsson AG, Zwahlen M, et al. Improvements in implant dentistry over the last decade: comparison of survival and complication rates in older and newer publications. Int J Oral Maxillofac Implants. 2014; 29(Suppl): 308-324.
2. Sherif S, Susarla HK, Kapos T, et al. A systematic review of screw-versus cement-retained implant-supported fixed restorations. J Prosthodont. 2014; 23: 1-9.
3. Papaspyridakos P, Chen CJ, Gallucci GO, et al. Accuracy of implant impressions for partially and completely edentulous patients: a systematic review. Int J Oral Maxillofac Implants. 2014; 29: 836-845.
4. Wismeijer D, Mans R, van Genuchten M, et al. Patients' preferences when comparing analogue implant impressions using a polyether impression material versus digital impressions (Intraoral Scan) of dental implants. Clin Oral Implants Res. 2014; 25: 1113-1118.
5. Schepke U, Meijer HJ, Kerdijk W, et al. Digital versus analog complete-arch impressions for single-unit premolar implant crowns: operating time and patient preference. J Prosthet Dent. 2015; 114: 403-406.
6. Stimmelmayr M, Beuer F, Edelhoff D, et al. Implant impression techniques for the edentulous jaw: A summary of three studies. J Prosthodont. 2016; 25: 146-150.
7. Abrahamsson I, Berglundh T, Lindhe J. The mucosal barrier following abutment dis/reconnection. An experimental study in dogs. J Clin Periodontol. 1997; 24: 568-572.
8. Berglundh T, Lindhe J. Dimension of the peri-implant mucosa. Biologic width revisited. J Clin Periodontol. 1996; 23: 971-973.
9. Rodríguez X, Vela X, Méndez V, et al. The effect of abutment dis/reconnections on peri-implant bone resorption: a radiologic study of platform-switched and non-platform-switched implants placed in animals. Clin Oral Implants Res. 2013; 24: 305-311.
10. Priest G. Virtual-designed and computer-milled implant abutments. J Oral Maxillofac Surg. 2005; 63(Suppl 2): 22-32.
11. Drago CJ. Two new clinical/laboratory protocols for CAD/CAM implant restorations. J Am Dent Assoc. 2006; 137: 794-800.
12. Grossmann Y, Pasciuta M, Finger IM. A novel technique using a coded healing abutment for the fabrication of a CAD/CAM titanium abutment for an implant-supported restoration. J Prosthet Dent. 2006; 95: 258-261.
13. Drago CJ, Peterson T. Treatment of an edentulous patient with CAD/CAM technology: A clinical report. J Prosthodont. 2007; 16: 200-208.
14. Telleman G, Raghoebar GM, Vissink A, et al. The use of a coded healing abutment as an impression coping to design and mill an individualized anatomic abutment: a clinical report. J Prosthet Dent. 2011; 105: 181-185.
15. Ramsey CD, Ritter RG. Utilization of digital technologies for fabrication of definitive implant-supported restorations. J Esthet Restor Dent. 2012; 24: 299-308.
16. Derhalli M. The digitalizing of implant dentistry: A clinical evaluation of 15 patients. Compend Contin Educ Dent. 2013; 34: 192-196.
17. Nayyar N, Yilmaz B, McGlumphy E. Using digitally coded healing abutments and an intraoral scanner to fabricate implant-supported, cement-retained restorations. J Prosthet Dent. 2013; 109: 210-215.

18. Mahn DH, Prestipino T. CAD/CAM implant abutments using coded healing abutments: A detailed description of the restorative process. Compend Contin Educ Dent. 2013; 34: 612-615.

19. Carpentieri JR, Lazzara RJ. A simplified impression protocol for fabrication of anatomical, cement-retained CAD/CAM abutments. Int J Periodontics Restorative Dent. 2014; 34(Suppl 3): 19S-25S.

20. Drago C. Treatment of a patient with a partially edentulous mandible using intraoral scanning (IOS) of a CADCAM healing abutment: Implant restorations. 3rd ed. Hoboken: Wiley-Blackwell; 2014. p. 125-150.

21. Eliasson A, Ortorp A. The accuracy of an implant impression technique using digitally coded healing abutments. Clin Implant Dent Relat Res. 2012; 14(Suppl 1): e30-e38.

22. Howell KJ, McGlumphy EA, Drago C, et al. Comparison of accuracy of Biomet 3i Encode Robocast technology and conventional implant impression techniques. Int J Oral Maxillofac Implants. 2013; 28: 228-240.

23. Al-Abdullah K, Zandparsa R, Finkelman M, et al. An in vitro comparison of the accuracy of implant impressions with coded healing abutments and different implant angulations. J Prosthet Dent. 2013; 110: 90-100.

24. Ng SD, Tan KB, Teoh KH, et al. Three-dimensional accuracy of a digitally coded healing abutment implant impression system. Int J Oral Maxillofac Implants. 2014; 29: 927-936.

25. Abduo J, Chen C, Le Breton E, et al. The effect of coded healing abutments on treatment duration and clinical outcome: A randomized controlled clinical trial comparing Encode and conventional impression protocols. Int J Oral Maxillofac Implants. 2017; 32: 1172-1179.

26. Fluegge T, Att W, Metzger M. A novel method to evaluate precision of optical implant impressions with commercial scan bodies-an experimental approach. J Prosthodont. 2017; 26: 34-41.

27. Ting-Shu S, Jian S. Intraoral digital impression technique: A review. J Prosthodont. 2015; 24: 313-321.

28. Müller P, Ender A, Joda T. Impact of digital intraoral scan strategies on the impression accuracy using the TRIOS Pod scanner. Quintessence Int. 2016; 47: 343-349.

29. Stimmelmayr M, Güth JF, Erdelt K, et al. Digital evaluation of the reproducibility of implant scanbody fit-an in vitro study. Clin Oral Investig. 2012; 16: 851-856.

30. Parpaiola A, Norton MR, Cecchinato D, et al. Virtual abutment design: A concept for delivery of CAD/CAM customized abutments- report of a retrospective cohort. Int J Periodontics Restorative Dent. 2013; 33: 51-58.

31. Chee WW, Torbati A, Albouy JP. Retrievable cemented implant restorations. J Prosthodont. 1998; 7: 120-125.

32. Rajan M, Gunaseelan R. Fabrication of a cement- and screw-retained implant prosthesis. J Prosthet Dent. 2004; 92: 578-580.

33. Nissan J, Snir D, Rosner O. Reliability of retrievable cemented implant-supported prostheses. J Prosthet Dent. 2016; 115: 587-591.

34. Berteretche MV, Hüe O. Topical anesthesia for prosthetic implant procedures. J Prosthet Dent. 2009; 102: 128-129.

35. Jaarda MJ, Razzoog ME, Gratton DG. Comparison of “look-alike” implant prosthetic retaining screws. J Prosthodont. 1995; 4: 23-27.

36. Bacchi A, Regalin A, Bhering CL, et al. Loosening torque of universal abutment screws after cyclic loading: influence of tightening technique and screw coating. J Adv Prosthodont. 2015; 7: 375-379.

37. Kurt M, Külünk T, Ural C, et al. The effect of different surface treatments on cement-retained implant-supported restorations. J Oral Implantol. 2013; 39: 44-51.

38. Adrian ED, Krantz WA, Ivanhoe JR, et al. A silicone obturator for the access canal in an implant-retained fixed prosthesis. J Prosthet Dent. 1991; 65:597.

39. Park SD, Lee Y, Kim YL, et al. Microleakage of different sealing materials in access holes of internal connection implant systems. J Prosthet Dent. 2012; 108: 173-180.

40. Bidra AS, Daubert DM, Garcia LT, et al. A systematic review of recall regimen and maintenance regimen of patients with dental restorations. Part 2: Implant-borne restorations. J Prosthodont. 2016; 25(Suppl 1): 16S-31S.

41. Bidra AS, Daubert DM, Garcia LT, et al. Clinical practice guidelines for recall and maintenance of patients with tooth-borne and implant-borne dental restorations. J Prosthodont. 2016; 25(Suppl 1): 32S-40S.

42. Bevington JC, Jemmett JAL, Onyon PF. Polymerization of methyl α-cyanoacrylate- II: Conditions for radical polymerization. Eur Polym J. 1976; 12: 255-257.

43. Del'Acqua MA, Chávez AM, Amaral AL, et al. Comparison of impression techniques and materials for an implant-supported prosthesis. Int J Oral Maxillofac Implants. 2010; 25: 771-776.

44. Wee AG, Schneider RL, Aquilino SA, et al. Evaluation of the accuracy of solid implant casts. J Prosthodont. 1998; 7: 161-169.

45. Cho SH, Schaefer O, Thompson GA, et al. Comparison of accuracy and reproducibility of casts made by digital and conventional methods. J Prosthet Dent. 2015; 113: 310-315.

46. Al-Imam H, Gram M, Benetti AR, et al. Accuracy of stereolithography additive casts used in a digital workflow. J Prosthet Dent. 2018; 119: 580-585.

47. Goldstein G, Vafiadis D, Kim J, et al. Finding Z: A mathematical method for predicting tissue position after implant abutment-restoration placement. J Prosthet Dent. 2014; 112: 322-324.

48. Kapos T, Evans C. CAD/CAM technology for implant abutments, crowns, and superstructures. Int J Oral Maxillofac Implants. 2014; 29(Suppl): 117-136.